

# Evaluation of Liver Disease in the Pediatric Patient

Ian D. D'Agata, MD\* and William F. Balistreri, MD†

## OBJECTIVES

After completing this article, readers should be able to:

1. List the age-specific causes of liver disease in neonates, infants, older children, and adolescents.
2. Explain why fractionation of serum bilirubin is necessary in infants who remain jaundiced after 2 weeks of age.
3. Characterize the syndrome of "neonatal hepatitis" and explain how it differs from viral hepatitis.
4. Characterize biliary atresia and identify findings from the history, physical examination, and laboratory evaluation that may suggest this diagnosis.
5. Describe a quick, cost-effective diagnostic approach to a neonate who presents with cholestasis.

## Introduction

Because clinicians often do not recognize the presence of underlying liver disease, precise documentation of the disorder can be delayed, which can lead to a subsequent delay in the initiation of effective therapies. Liver transplantation is a reality for pediatric patients who have severe or end-stage liver disease, and other therapies also are now available for treating many liver diseases.

The estimated incidence of neonatal liver disease is as high as 1 in 2,500 live births. Early recognition is particularly important in neonates and infants because a delay in diagnosis may have a negative effect on the prognosis. For example, it is well recognized that when biliary atresia is diagnosed after 2 months of age, the success rate of surgical repair (Kasai hepatopuertoenterostomy) declines sharply. Furthermore, because liver dysfunction is progressive, early recognition allows for better nutritional support of the patient and a potentially slower decline in liver function. The result can be improved growth and fewer complications. This is of considerable importance because orthotopic liver transplantation generally is

more successful in infants who weigh more than 10 kg at the time of surgery.

Unfortunately, the timely recognition of severe liver disease in the pediatric patient remains a major problem. One contributing factor is that injury to the pediatric liver manifests in a finite number of ways; hence, different disorders often have virtually identical initial presentations. For example, neonates who have liver injury almost always present with jaundice. Unfortunately, the difference between "physiologic hyperbilirubinemia" and hyperbilirubinemia indicative of severe liver disease often is unappreciated. Data from the United Kingdom have documented several factors contributing to late referral of infants who have liver disease (Table 1). This also is a problem in the United States, where late referrals for biliary atresia and other serious causes of liver dysfunction still occur.

## Etiology

The causes of liver disease in pediatric patients vary with age (Table 2). Some are associated with certain age groups, such as biliary atresia and idiopathic neonatal hepatitis, which are observed only at birth or shortly thereafter. Conversely, alcohol or acetaminophen intoxication and Wilson disease are typical of older children, especially adolescents. Furthermore, although "neonatal hepatitis" may be caused by

viruses, it is not the same entity as the viral hepatitis observed in older children and adolescents. Understanding that specific diseases are more common, if not exclusive, to certain age groups is of great help in focusing the evaluation and defining the cause of underlying liver disease. It is important to remember that despite the long list of disorders associated with liver disease in the neonate, most are encountered rarely. Further, although lists of the various etiologies leading to pediatric liver disease are extremely lengthy, about 10 diseases constitute approximately 95% of all cases of cholestasis seen, and of these, biliary atresia and neonatal hepatitis are responsible for more than 60%.

In general, the clinician initially suspects liver disease in the neonate who presents with classic signs, such as persistent jaundice, hepatomegaly, coagulopathy, or failure to thrive. At other times, incidental findings of abnormalities on serum chemistries may suggest the diagnosis. Jaundice, confusion, and coma occur in older children and adolescents who have acute hepatitis or following toxin exposure. Pruritus, seen in older children who have cholestasis, may manifest as irritability in infants. No matter what the presentation, a stepwise analysis of historical data, clinical findings, and laboratory values allows initiation of

## ABBREVIATIONS

AIH:	autoimmune hepatitis
ALT:	alanine aminotransferase
AP:	alkaline phosphatase
AST:	aspartate aminotransferase
CT:	computed tomography
GGT:	gamma glutamyl transpeptidase
HAV:	hepatitis A virus
HBV:	hepatitis B virus
HCV:	hepatitis C virus
HDV:	hepatitis D virus
HEV:	hepatitis E virus
LFT:	liver function test
MRI:	magnetic resonance imaging
PT:	prothrombin time
PTT:	partial thromboplastin time

\*Pediatric Gastroenterology & Liver Diseases, Valley Children's Hospital, Madera, CA.

†Chief, Division of Gastroenterology & Nutrition, Children's Hospital Medical Center, Cincinnati, OH.

**TABLE 1. Reasons for a Delay in Referral of Infants Who Have Liver Disease**

- Lack of follow-up of neonatal jaundice (including failure to fractionate serum bilirubin)
- Inadequate investigation of hemorrhagic disease/coagulopathy
- Misdiagnosis of cholestasis (conjugated hyperbilirubinemia) as human milk jaundice (unconjugated hyperbilirubinemia)
- False security due to a fall in serum bilirubin concentrations or presence of pigmented stools

the most appropriate and cost-effective strategy to diagnose and treat the underlying condition.

## History and Signs of Liver Disease

### NEONATE

Although an infant may have been jaundiced at birth (physiologic hyperbilirubinemia) or may be breastfeeding, it is important *not* to attribute jaundice in an infant older than 14 days to one of these causes. Jaundice in any infant after 2 weeks of age should raise the suspicion of liver disease and prompt appropriate evaluation. A careful history may provide clues about the existence and type of liver disease. For example, the onset of liver disease associated with dietary changes may suggest an inborn error of carbohydrate metabolism, such as an inability to metabolize galactose or fructose. A positive family history for a suspected genetic disorder (such as Alagille syndrome) should focus the initial evaluation in that direction. A recurrent clinical phenotype within a family suggests an inherited disorder such as tyrosinemia or Byler syndrome (progressive familial intrahepatic cholestasis).

Idiopathic neonatal hepatitis appears to be more common among males, especially preterm or low-birthweight infants. In contrast, bili-

ary atresia occurs more commonly among females of normal weight, and the rate of intrafamilial recurrence approaches zero. Also, an associated polysplenia syndrome favors a diagnosis of biliary atresia. Patients who have biliary atresia experience an earlier onset of jaundice and of acholic stools compared with those who have neonatal hepatitis.

Maternal fever or other signs of infection suggest sepsis as the underlying cause of jaundice in the neonate. Gram-negative bacteria (eg, *Escherichia coli*) causing urinary tract infections are especially common.

In cholestatic disease, jaundice almost invariably is present in the first month of life. Unfortunately, jaundice is not recognized in infants until the first health supervision visit, which leaves little time for diagnosis and surgical correction of biliary atresia, which ideally should occur within the first 2 months of life. The Figure details a rapid step-wise approach to rule out biliary atresia in an infant presenting with cholestasis before 2 months of age.

Acholic stools also are highly characteristic of cholestasis in infancy. In the presence of extra- or intrahepatic obstruction, little or no bilirubin is excreted into the intestine, resulting in no color to the neoformed fecal material. Although some pigment may be present in the stools of neonates who have biliary obstruction because of desquamation of cells containing pigment into the stool, these stools usually are much lighter than those found in healthy infants. Furthermore, breaking the stool into pieces will show that the pigment is only superficial, with the internal part exhibiting a clay coloring at best.

### OLDER CHILD

In older children, a history documenting anorexia, fever, vomiting, abdominal pain, darkening of the urine, especially following ingestion of crustaceans or shellfish of dubious provenance, should lead to the suspicion of hepatitis A virus (HAV) infection. HAV infection also is the likely etiology of liver disease in any child who has a his-

tory of a flu-like illness and suddenly develops jaundice with elevated aminotransferase values in the absence of other known hepatotoxic exposures. Hepatitis A is often anicteric in young children (<5 y) and frequently is unrecognized.

Signs of liver disease in patients who have received tattoos, who use intravenous drugs, or in whom an underlying condition led to increased exposure to parenterally administered blood products (hemodialysis, hemophilia, surgery) prior to widespread screening (1992) can suggest hepatitis C infection. Teenagers who become jaundiced always should be questioned privately about intravenous drug abuse and exposure to crack cocaine, the intranasal use of which recently has been shown to be associated with hepatitis C (sharing of glass paraphernalia) and possibly hepatitis B infection. If the course of a documented hepatitis B infection is particularly severe, coinfection or superinfection with hepatitis D (delta) should be suspected. Male homosexuals are at an increased risk to develop viral hepatitis.

It always is important to elicit a history of exposure to potentially hepatotoxic medications, including isoniazid, nitrofurantoin, sulfonamides, and nonsteroidal anti-inflammatory agents, such as acetaminophen and ibuprofen. If an overdose or an intoxication is the cause of liver dysfunction, children can present with altered mental status and even coma. Confusion and coma suggest liver failure or metabolic disease leading to hyperammonemia, hypoglycemia, or a combination of both. Female teenagers who develop jaundice and have histories of acne, intermittent arthritis, and fatigue may have autoimmune hepatitis, although this entity can occur less commonly in boys and in younger children.

Patients who have immunodeficiencies and become jaundiced may have an infection with cytomegalovirus, Epstein-Barr virus, or retrovirus. A history of sore throat in an individual who also has jaundice, splenomegaly, and lymphadenopathy suggests Epstein-Barr virus infection. A history of right upper quadrant colicky pain and nausea (espe-

**TABLE 2. Most Frequent Causes of Liver Disease in Pediatric Patients According to Age**

Neonates and Infants	Older Children and Adolescents
<ul style="list-style-type: none"> <li>• Cholestatic disorders               <ul style="list-style-type: none"> <li>—Biliary atresia</li> <li>—Choledochal cyst</li> <li>—Paucity of intrahepatic bile ducts (eg, Alagille syndrome)</li> <li>—Progressive familial intrahepatic cholestasis syndromes (Byler disease and syndrome)</li> <li>—Benign recurrent intrahepatic cholestasis</li> <li>—Caroli disease and syndrome</li> <li>—Inspissated bile (S/P hemolytic disease)</li> <li>—Cholelithiasis</li> </ul> </li> </ul>	<ul style="list-style-type: none"> <li>• Hepatitis               <ul style="list-style-type: none"> <li>—Viral hepatitis (hepatitis B virus, hepatitis C virus)</li> <li>—Autoimmune hepatitis</li> <li>—Toxic</li> <li>—Pharmacologic (eg, acetaminophen)</li> </ul> </li> </ul>
<ul style="list-style-type: none"> <li>• Idiopathic neonatal hepatitis and mimickers               <ul style="list-style-type: none"> <li>—Cystic fibrosis</li> <li>—Alpha 1-antitrypsin deficiency</li> <li>—Hypopituitarism/hypothyroidism</li> <li>—Neonatal iron storage disease</li> </ul> </li> </ul>	<ul style="list-style-type: none"> <li>• Liver disease associated with chronic inflammatory bowel disease, sclerosing cholangitis</li> </ul>
<ul style="list-style-type: none"> <li>• Viral hepatitis or other infectious diseases in the neonate               <ul style="list-style-type: none"> <li>—Cytomegalovirus</li> <li>—Herpes simplex virus/herpes zoster virus/human herpesvirus 6</li> <li>—Epstein-Barr virus</li> <li>—Parvovirus B19</li> <li>—Rubella</li> <li>—Reovirus—type 3</li> <li>—Adenovirus</li> <li>—Enterovirus</li> <li>—Bacterial sepsis/urinary tract infection</li> <li>—Syphilis</li> <li>—Tuberculosis</li> <li>—Toxoplasmosis</li> </ul> </li> </ul>	<ul style="list-style-type: none"> <li>• Parasitic infections</li> <li>• Toxins and pharmacologic remedies</li> </ul>
<ul style="list-style-type: none"> <li>• Metabolic disease               <ul style="list-style-type: none"> <li>—Disorders of peroxisomal function (Zellweger syndrome)</li> <li>—Disorders of bile acid metabolism</li> <li>—Disorders of urea cycle (arginase deficiency)</li> <li>—Disorders of amino acid metabolism (tyrosinemia)</li> <li>—Disorders of lipid metabolism (Niemann-Pick type C/Gaucher/Wolman)</li> <li>—Disorders of carbohydrate metabolism (galactosemia, fructosemia, type IV glycogen storage disease)</li> </ul> </li> </ul>	<ul style="list-style-type: none"> <li>• Malignancies</li> <li>• Wilson disease</li> <li>• Occlusion of the hepatic veins</li> <li>• Fatty liver of pregnancy</li> <li>• Fatty liver of obesity (nonalcoholic steatohepatitis)</li> <li>• Hypotension/ischemia/cardiac failure</li> </ul>
<ul style="list-style-type: none"> <li>• Toxic/pharmacologic injury (eg, acetaminophen, total parenteral nutrition, hypervitaminosis A)</li> <li>• Tumors (intra- and extrahepatic)</li> </ul>	

cially if following ingestion of fatty foods) points to gall bladder disease, which is more common in older children. Signs and symptoms of obesity or cardiac, endocrine, and intestinal disease must be evaluated because abnormalities of serum aminotransferase may reflect secondary

liver involvement in systemic disease (the liver as an “innocent bystander”). Elevation of aminotransferase concentrations (especially AST) also can be a manifestation of muscle disease.

Older children and adolescents who have liver disease initially may

complain of anorexia, fatigue, or scleral icterus. Cholestasis may lead to complaints of pruritus and a particularly dark and foamy urine. The color is due to choloria (bile pigments in the urine); the foaminess suggests the presence of choleuria (bile salts in the urine). Bile salts

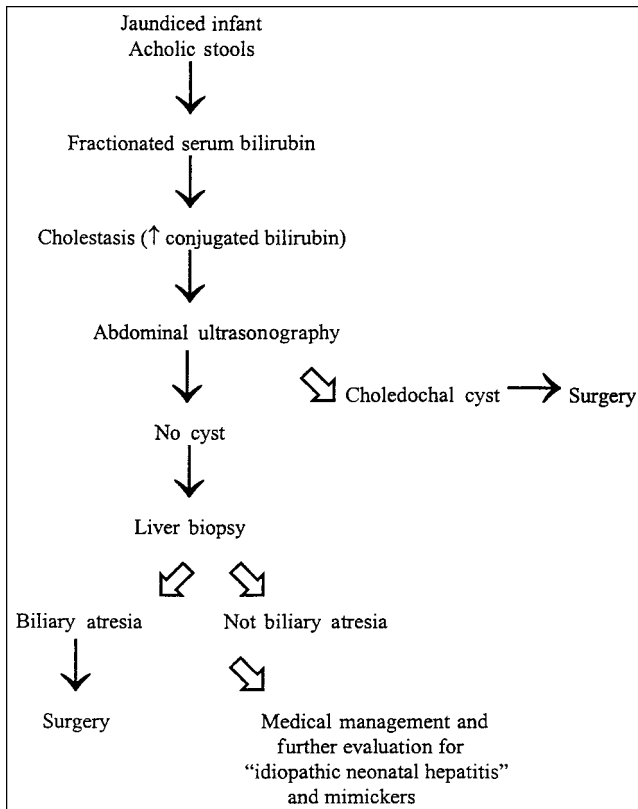


FIGURE. Rapid diagnosis of biliary atresia.

are detergent molecules that lower the superficial tension of solutions, thereby creating visible foaminess.

### Physical Examination

Common physical findings associated with specific liver diseases are listed in Tables 3 through 6. Among this plethora of physical findings, the most common are hepatomegaly and jaundice. Hepatomegaly often is the only manifestation of liver disease, although palpation of the liver edge can be misleading because of normal variations in contour, body habitus, or displacement of the liver by adjoining organs or extrinsic or intrinsic masses. Therefore, measurement of liver span is a useful adjunct to palpation at initial presentation and at follow-up. The liver span is the distance between the liver edge and the upper margin of dullness obtained by percussion at the right midclavicular line. The mean span changes from 4.5 to 5 cm at 1 week of age to 6 to 7 cm in early adolescence.

Palpation of the abdomen also may reveal the presence of an enlarged spleen, which is usually of

epigastrium signifies either the presence of cirrhosis or Riedel lobe (a normal anatomic elongation of the right lobe that may be mistaken for hepatomegaly). Pain to palpation with hepatomegaly simply may reflect a mild viral insult with distention of the Glisson capsule due to edema that is responsible for the perceived pain localized to the liver.

Auscultation of the liver may allow the clinician to detect vascular bruits due to anatomic malformations of the vessels or increased flow to the liver. Ascites, if present, suggests increased portal venous pressure and worsening liver function. Massive hepatosplenomegaly may indicate a storage disorder or a malignancy, although a particularly impressive hepatomegaly in isolation often is associated with congenital hepatic fibrosis. This usually is associated with minimal liver dysfunction, despite the worrisome hepatomegaly. In this condition, the kidneys must be evaluated to rule out a coexisting autosomal recessive or dominant polycystic kidney disease.

Certain physical findings are highly suggestive of specific liver

normal size early in the course of liver disease. If the spleen is enlarged, one of the many causes of portal hypertension or storage disease should be suspected. Normally, the liver edge is round and soft and the surface smooth.

A hard, thin edge and a nodular surface may suggest the presence of fibrosis or cirrhosis. The latter condition also often is associated with a small liver.

Palpation of the liver in the

diseases. In neonates who suffer congenital infections, associated features often include microcephaly, chorioretinitis, purpura, low birth-weight, and generalized organ failure. Dysmorphic features may be characteristic of certain chromosomal disorders. Patients who have Alagille syndrome usually have a characteristic facies (beaked nose, high forehead), butterfly vertebrae, a murmur on cardiovascular auscultation due to peripheral pulmonic stenosis, and a posterior embryotoxon on ophthalmologic examination. The presence of intermittent emesis in the neonate, especially if unremitting, may indicate an inborn error of fatty acid metabolism, which usually also is associated with poor feeding and irritability. The onset of symptoms (such as vomiting) following the introduction of a new food containing galactose or fructose could suggest galactosemia or hereditary fructose intolerance. Congenital ascites may suggest liver failure, cirrhosis, or a storage disorder.

Infants who have cholestasis often suffer from intense pruritus, which is characteristic of obstructive liver disease, that primarily is manifested by irritability.

### Laboratory Evaluation

#### TYPES OF LIVER INJURY

The laboratory findings of liver injury can be divided broadly into two patterns: 1) cholestatic or obstructive bile duct injury and 2) hepatocellular or liver cell injury. However, there is often considerable overlap between injury types in a patient who has liver disease.

Cholestasis is characterized by an accumulation of compounds that cannot be excreted because of occlusion or obstruction of the biliary tree. Hence, the serum concentration of substances (bile pigments, enzymes, bile salts) that normally are present within or eliminated via bile will increase in cholestatic conditions. Alkaline phosphatase (AP), gamma glutamyl transpeptidase (GGT), and conjugated bilirubin, all of which require a clear biliary tree for elimination, will be elevated. Because most infants who undergo liver transplantation present initially



**TABLE 3. Diseases Causing Jaundice/Elevated Liver Enzymes**

<p><b>Infants</b></p> <ul style="list-style-type: none"> <li>• Infections           <ul style="list-style-type: none"> <li>—Bacterial: sepsis (<i>Escherichia coli</i>)</li> <li>—Viral: Cytomegalovirus, rubella, Coxsackievirus, echovirus, herpesvirus, adenovirus</li> </ul> </li> <li>• Metabolic disorders           <ul style="list-style-type: none"> <li>—Inherited: Alpha 1-antitrypsin deficiency, galactosemia, hereditary fructose intolerance, cystic fibrosis, Niemann-Pick disease, tyrosinemia</li> <li>—Acquired: Cholestasis and liver disease associated with total parenteral nutrition, hypothyroidism, panhypopituitarism</li> </ul> </li> <li>• Idiopathic disorders: Neonatal hepatitis, progressive familial intrahepatic cholestasis (eg, Byler disease), Ivemark syndrome, cerebrohepato-renal (Zellweger) syndrome</li> <li>• Malformation of the bile ducts           <ul style="list-style-type: none"> <li>—Atresia/paucity: Biliary atresia, intrahepatic bile duct paucity nonsyndromic and syndromic (Alagille syndrome)</li> </ul> </li> <li>• Cystic malformations: Choledochal cysts, cystic dilation of the intrahepatic bile ducts (Caroli disease), congenital hepatic fibrosis, polycystic disease of the liver and kidneys</li> </ul>
<p><b>Children and Adolescents</b></p> <ul style="list-style-type: none"> <li>• Acute viral hepatitis (HAV)</li> <li>• Inherited disorders: Wilson disease, cystic fibrosis, hepatic porphyrias, Dubin-Johnson syndrome, Rotor syndrome</li> <li>• Malignancies: leukemia, lymphoma, liver tumors</li> <li>• Chemicals: hepatotoxic agents, toxins (insecticides, hydrocarbons, alcohol, organophosphates, hypervitaminosis A, mushrooms, acetaminophen)</li> <li>• Parasitic infections: schistosomiasis, leptospirosis, visceral larva migrans</li> <li>• Idiopathic or secondary lesions: chronic hepatitis, inflammatory bowel disease (ulcerative colitis), rheumatoid arthritis, obesity</li> </ul>

with cholestatic disease, it is especially important to be able to recognize, differentiate, and attempt to make a specific diagnosis (eg, biliary atresia) when cholestasis is present.

Conversely, necrosis of hepatocytes following a viral or toxic insult to the liver (eg, acetaminophen overdose or viral hepatitis) will cause primarily an elevation of enzymes found within the hepatocyte, such as the aminotransferases (ALT and AST). In hepatocellular disease, the serum levels of GGT and AP do not rise to the same degree as the aminotransferases.

This distinction between the two basic types of liver injury is not always clear-cut. For example, cholestasis inevitably leads to a certain

degree of hepatocellular dysfunction because of the noxious accumulation of bile within the hepatocytes and the biliary tree. In hepatocellular disease, the reduced bile flow (sludging) that ensues from necrosis of the hepatocytes also causes a mild rise in serum markers of obstruction (AP, GGT).

The two basic types of liver disease can be distinguished early in the course of the disease process, but more often, the underlying type of liver disease is diagnosed by interpretation of a constellation of clinical and laboratory criteria, including liver biopsy. This is especially true for neonates and infants, in whom the greatest overlap between liver injury types occurs. It is most important to recognize the

**TABLE 4. Diseases Causing Hepatomegaly**

<p><b>Infants and Children</b></p> <ul style="list-style-type: none"> <li>• Storage disorders           <ul style="list-style-type: none"> <li>—Acute: Reye syndrome (fat)</li> <li>—Chronic: glycogenoses, mucopolysaccharidoses, Gaucher disease, Niemann-Pick disease, gangliosidosis, Wolman disease</li> </ul> </li> <li>• Nutritional problems: total parenteral alimentation (caloric overload), kwashiorkor, diabetes</li> <li>• Infiltrative disorders: leukemia, lymphoma, Langerhans cell histiocytosis, granulomas (sarcoidosis, tuberculosis)</li> <li>• Congenital hepatic fibrosis</li> <li>• Tumors           <ul style="list-style-type: none"> <li>—Primary: hepatoblastoma, hematoma, hemangio-endothelioma</li> <li>—Metastatic: neuroblastoma, Wilms tumor, gonadal tumors</li> </ul> </li> </ul>
--

presence of cholestasis in patients in this age group, even in preterm infants in whom the persistence of jaundice beyond 14 days of life mandates an evaluation.

Table 7 summarizes the goals of a staged evaluation of infants who have jaundice. Table 8 lists our recommended sequence of data collection in the evaluation of an infant who has suspected cholestasis. An expedited evaluation is suggested for infants who present at 2 months of age with cholestasis to rule out biliary atresia quickly (Figure).

#### LIVER FUNCTION TESTS

Because the liver has a large functional reserve, abnormal laboratory values often are the only indication of hepatic disease and may be seen long before overt clinical findings. In the usual scenario, a physician who suspects liver disease will order specific "liver function tests" (LFTs) to assess hepatic "function." Following these values sequentially may provide information about prognosis, response to therapy, and extent of

**TABLE 5. Diseases Causing Liver Failure**

<b>Neonates and Infants</b>
<ul style="list-style-type: none"> <li>• Infections: herpesviruses, echo/adenoviruses, sepsis</li> <li>• Metabolic disorders: hereditary fructose intolerance, mitochondrial diseases, tyrosinemia, galactosemia, neonatal iron storage disease</li> <li>• Ischemia/shock: congenital cardiac disease, myocarditis, severe hypotension</li> <li>• Drugs/toxins: valproate, acetaminophen</li> </ul>
<b>Children and Adolescents</b>
<ul style="list-style-type: none"> <li>• Infections: hepatitis, herpesviruses, echo/adenoviruses, sepsis</li> <li>• Drugs/toxins: valproate, acetaminophen, mushrooms (Amanita)</li> <li>• Malignancy</li> <li>• Ischemia/shock: congenital cardiac disease, myocarditis, severe hypotension</li> <li>• Metabolic: Wilson disease, fatty liver of pregnancy</li> </ul>

dysfunction. However, the term LFTs is not entirely accurate because only two of the parameters commonly obtained are true measures of hepatic function—the prothrombin time (PT) and serum albumin level—both of which assess synthetic ability. All of the other parameters are essentially indirect measures of liver function, and some of these values are altered in settings other than liver disease. For example, elevations in aspartate aminotransferase (AST) accompany red blood cell hemolysis, muscle breakdown, and pancreatic disease. For a variety of reasons (cumbersome equipment and methodologies, expense, lack of established normal values), true liver function tests, such as caffeine clearance or lidocaine metabolism, do not yet have routine clinical application.

Biochemical abnormalities associated with liver disease are not limited to those of the LFTs. For example, nonketotic hypoglycemia

**TABLE 6. Miscellaneous Physical Findings Associated With Liver Disease**

<b>Infants</b>
<ul style="list-style-type: none"> <li>• Microcephaly: congenital cytomegalovirus, rubella, toxoplasmosis</li> <li>• Characteristic facies: arteriohepatic dysplasia (Alagille syndrome)</li> <li>• Cataracts: galactosemia</li> <li>• Retinal pigmentation and posterior embryotoxon: Alagille syndrome</li> <li>• Abnormal auscultation of lungs: cystic fibrosis</li> <li>• Neuromuscular abnormalities (tremors, flaccidity): lipid storage disease, Wilson disease, disorders of oxidative phosphorylation</li> </ul>
<b>Children</b>
<ul style="list-style-type: none"> <li>• Pruritus: chronic cholestasis</li> <li>• Hemangiomas: hemangiomatosis of the liver</li> <li>• Kayser-Fleischer rings: Wilson disease</li> <li>• Glossitis: cirrhosis</li> <li>• Enlarged kidneys: congenital hepatic fibrosis or polycystic disease</li> <li>• Arthritis and erythema nodosum: liver disease with chronic inflammatory bowel disease</li> <li>• Arthritis, acne, fatigue: autoimmune hepatitis</li> </ul>

suggests a defect in beta-oxidation of fatty acids and ketone production. Marked ketosis, a rare finding in infants, may indicate an organic acidemia, glycogen storage disease, or a deficit in gluconeogenesis. An increase in anion gap metabolic acidosis also suggests an organic acidemia. Hypo- and hyperthyroidism may be associated with jaundice. A sweat chloride determination may be necessary to rule out cystic fibrosis. Ferritin and iron studies are useful to help diagnose neonatal iron storage disease. Determination of

**TABLE 7. Goals of a Staged Evaluation of Infants Who Have Jaundice**

<ul style="list-style-type: none"> <li>• Recognize cholestasis (versus unconjugated, “physiologic” hyperbilirubinemia)</li> </ul>
<ul style="list-style-type: none"> <li>• Assess severity of the liver injury</li> </ul>
<ul style="list-style-type: none"> <li>• Separate specific entities (eg, metabolic versus viral versus anatomic)</li> </ul>
<ul style="list-style-type: none"> <li>• Differentiate biliary atresia from idiopathic neonatal hepatitis</li> </ul>
<ul style="list-style-type: none"> <li>• Differentiate idiopathic neonatal hepatitis from progressive familial intrahepatic cholestasis and bile duct paucity</li> </ul>

serum and urinary bile acid levels will aid in eliminating the possibility of an inborn error of bile acid metabolism. Urinary succinylacetone levels may indicate the presence of tyrosinemia. A urinalysis and urine culture always should be obtained in any infant who has jaundice because urosepsis commonly is associated with conjugated hyperbilirubinemia (eg, *E coli* urinary tract infection). Anemia and hemolysis may indicate the presence of a hemolytic condition responsible for jaundice (usually unconjugated) and not associated with liver disease.

**TOTAL/CONJUGATED BILIRUBIN**

Of all laboratory tests performed, bilirubin fractionation is the most important, especially in any infant who has more than 2 weeks of jaundice. If conjugated or direct bilirubin is present, evaluation should be aggressive. (Many managed care organizations are not measuring conjugated bilirubin levels, even after 2 weeks of life in the presence of jaundice.) Unconjugated bilirubinemia makes significant liver disease unlikely, but the infant may need to be evaluated for possible hemolysis, congenital disorders of bilirubin metabolism (eg, Crigler-Najjar types I and II), and thyroid dysfunction.

Conjugated hyperbilirubinemia

**TABLE 8. Stepwise Evaluation of Infants Who Have Suspected Cholestatic Liver Disease**

<ul style="list-style-type: none"> <li>• Confirm cholestasis               <ul style="list-style-type: none"> <li>—Clinical evaluation (family history, feeding history, physical examination)</li> <li>—Fractionation of serum bilirubin and determination of serum bile acid levels</li> <li>—Assessment of stool color</li> <li>—Index of hepatic synthetic function (prothrombin time and albumin)</li> </ul> </li> </ul>
<ul style="list-style-type: none"> <li>• Recognize specific entities               <ul style="list-style-type: none"> <li>—Viral and bacterial cultures (blood, urine, cerebrospinal fluid)</li> <li>—Hepatitis B surface antigen and other viral and syphilis (VDRL) titers in selected, high-risk patients</li> <li>—Metabolic screen (urine-reducing substances, urine and serum amino acids)</li> <li>—Thyroxine and thyroid-stimulating hormone</li> <li>—Alpha 1-antitrypsin phenotype</li> <li>—Sweat chloride</li> <li>—Qualitative analysis of urinary bile acid profile</li> <li>—Ultrasonography</li> </ul> </li> </ul>
<ul style="list-style-type: none"> <li>• Differentiate biliary atresia from neonatal hepatitis               <ul style="list-style-type: none"> <li>—Hepatobiliary scintigraphy or duodenal intubation for bilirubin content</li> <li>—Liver biopsy</li> </ul> </li> </ul>

generally is considered pathologic. When the serum conjugated bilirubin value is greater than 17  $\mu\text{mol/L}$  (1  $\text{mg/dL}$ ) or greater than 15% of the total bilirubin value, it should be considered abnormal and evaluated immediately. Unconjugated bilirubin reflects excessive bilirubin production (eg, from hemolysis) or a delay in hepatic bilirubin conjugating capacity. Although harmless in the older patient, unconjugated hyperbilirubinemia of extreme degrees may be associated with kernicterus in the neonate. However, the conjugated fraction is associated with serious liver disease and indicates cholestasis. Conjugated hyperbilirubinemia should not be confused with physiologic jaundice of the newborn (in which the unconjugated bilirubin level rises) that results from immaturity of the glucuronyl transferase enzyme system, which is responsible for conjugation of bilirubin. It also must not be confused with the jaundice associated with breastfeeding that involves a slight temporal delay in conjugating capacity, generally believed to be due to components within human milk.

The healthy, mature liver

removes unconjugated bilirubin from the blood and mediates conjugation of unconjugated bilirubin with two molecules of glucuronic acid. Conjugation of bilirubin turns an essentially liposoluble substance (unconjugated bilirubin) into a water-soluble one (conjugated bilirubin) that can be excreted in bile, an aqueous medium. It is the liposoluble nature of unconjugated bilirubin that allows it to cross the blood-brain barrier and potentially to cause kernicterus.

Bilirubin fractions often are referred to as “direct” and “indirect.” The “direct” term derives from the fact that conjugated bilirubin was detected historically by using the Van den Bergh reaction, in which a water-soluble medium (Ehrlich reagent) was added to the serum sample under examination, prompting a direct color change. Alcohol then was added to solubilize the bilirubin and obtain a color change (hence, an “indirect” reaction). Besides the three basic forms of bilirubin (unconjugated, conjugated monoglucuronide, and conjugated diglucuronide), there is a fourth form (delta bilirubin), which is bound covalently to albumin. Some-

what confusingly, calculation of the exact value of conjugated bilirubin in some institutions requires the addition of the delta value to that of the “conjugated” bilirubin. A low delta bilirubin value or one that does not increase in the presence of a known cholestatic disorder (in which there is a progressive increase in conjugated bilirubin) may signify a poor prognosis because it reflects low albumin availability for covalent bonding. Low albumin values reflect diminished hepatic synthetic ability.

#### URINALYSIS

The urine tends to be darker in the setting of cholestatic liver disease. Conjugated bilirubin is excreted in the urine, and bilirubinuria may appear before obvious clinical jaundice. This can be shown quickly and easily on a urine dipstick examination, making a simple urinalysis an important initial evaluation for an infant who has jaundice. Urobilinogen, which is formed from the degradation of conjugated bilirubin by bacteria present in the intestinal lumen, also is found in urine. Most urobilinogen is excreted in the stool as coprobinogen; 20% undergoes enterohepatic recirculation. Only a small fraction escapes into the urine, but it is increased in the presence of hepatocellular damage because of decreased liver uptake and recirculation. Clearly, urinary urobilinogen is nearly absent in the presence of an obstructive process because less bilirubin enters the intestine and less is converted to urobilinogen. Interestingly, delta bilirubin, because of its covalent bonding to albumin, is not excreted in urine and, therefore, tends to remain elevated in the serum for some time after an initial cholestatic insult because its disappearance depends on the degradation of the albumin-bilirubin complex.

#### AMINOTRANSFERASE ACTIVITY

The levels of alanine aminotransferase (ALT) (formerly known as serum glutamic pyruvate transferase [SGPT]) and AST (formerly known as serum glutamic oxaloacetic transaminase [SGOT]) are the most sensitive tests of hepatocyte necrosis. High elevations of these enzymes, which are released from

damaged hepatocytes, indicate hepatocellular injury. Slightly abnormal values also may be associated with cholestatic processes because the back flow or stasis of bile is toxic to hepatocytes. These enzymes catabolize the reversible transfer of the alpha-amino group of the amino acids alanine and aspartic acid to the alpha-keto group of alpha-ketoglutaric acid, leading to the formation of pyruvic acid (ALT) and oxaloacetic acid (AST). ALT is more specific for the presence of liver disease because it is found only in low concentrations in other tissues (eg, muscle). Conversely, AST is present in high concentrations in many tissues, including cardiac and skeletal muscle, kidney, pancreas, and erythrocytes. The coenzyme for both enzymes is vitamin B6, so consistent abnormally low values of AST and ALT suggest underlying vitamin B6 deficiency.

In general, measurements of aminotransferases do not yield information concerning specific diagnoses, but particularly high levels suggest drug hepatotoxicity (eg, acetaminophen overdose), hypoxia/shock, and viral hepatitis. These levels do not have any prognostic value; patients who have very high abnormal values can do well, especially in the case of acetaminophen toxicity. However, they are useful in monitoring the patient's clinical progress. For example, progressively decreasing AST/ALT values in a young patient who has known HAV infection and otherwise is doing well is a reassuring sign that the liver disease is resolving. Conversely, falling values of AST/ALT in the presence of a shrinking liver, rising PT and partial thromboplastin time (PTT), and no clinical improvement is an ominous sign. It suggests a decreased functioning hepatocyte mass due to necrosis that has diminished the amount of enzymes available to be released into the circulation.

#### ALKALINE PHOSPHATASE (AP) LEVELS

AP is localized primarily to the canalicular membrane of the liver cell; therefore, an elevated serum AP level usually indicates obstructive liver disease (eg, bile duct obstruc-

tion). However, AP is found in other tissues, including bone, kidney, and the small intestine. High AP values normally are found in children during periods of accelerated growth, such as during pubertal growth spurts. Particularly high values should lead to the suspicion of possible bone pathology (eg, rickets), especially if the rise in AP is not associated with a rise in GGT. If the levels of the latter enzyme also are elevated, bone disease is unlikely. This simple observation alleviates the need for fractionation of the AP value into the individual isoenzymes to determine the exact source of its rise. Because zinc is a coenzyme of AP-catalyzed reactions, chronically low levels of AP may mean a low serum zinc level.

***Jaundice in any infant after 2 weeks of age should raise the suspicion of liver disease and prompt appropriate evaluation.***

#### SERUM AND URINE BILE ACIDS

A production and transport process that occurs in the liver (bile acid synthesis, conjugation, and secretion) maintains cholesterol balance, facilitates bile flow, and provides surface active detergent molecules that promote intestinal absorption of lipid. Proper functioning of this system promotes a balance between absorption of bile acids from the intestine and their uptake by hepatocytes. In the absence of alterations of the ileum (eg, short gut, Crohn disease), serum levels of bile acids are a reliable index of the integrity of the enterohepatic circulation. Although serum bile acids do not provide specific information on the type of liver disease present, they are elevated in patients who have either acute or chronic liver disease, in whom bilirubin levels still may be normal. The alteration in serum bile acid levels not only may be quantitative, but it may be qualitative as well. In certain diseases, "atypical" bile acids such as lithocholic acid accumulate instead of the normal cholic and chenodeoxycholic acids.

Interpretation of elevated levels of serum bile acids in neonates and infants is complicated by the presence of a relative "physiologic cholestasis," which can result in ele-

vated serum bile acid levels even in healthy infants. However, specific defects of bile acid metabolism are associated with cholestasis due to either underproduction of the normal trophic and choleric bile acids or overproduction of hepatotoxic bile acids. Precise identification of precursors and metabolites allows the determination of specific inborn errors of bile acid metabolism. With recent technological advances, such as fast atom bombardment-mass spectrometry, it has been possible to analyze urine samples rapidly from individuals in whom bile acid disorders are suspected and to delineate specific inborn errors of bile acid metabolism, such as 3 beta hydroxysteroid dehydrogenase/isomerase deficiency and delta<sup>4</sup>-3-oxosteroid-5

beta reductase deficiency, which manifest as severe liver disease.

#### GAMMA-GLUTAMYL TRANSFERASE (GGT)

GGT is found in the small bile ductule epithelium of the liver as well as within hepatocytes. However, it also is present in the pancreas, spleen, brain, breast, small intestine, and especially the kidney. Hence, elevation of serum GGT does not specifically indicate liver disease. Because GGT levels do not rise in individuals who have bone or intestinal disease, such a finding is particularly helpful in elucidating the origin of an elevated AP level. 5'-nucleotidase is another liver enzyme that does not rise in bone disease, and in some centers it is used in lieu of GGT as a marker of possible liver disease. Because GGT values (similar to AP) change with age, the laboratory must use age-appropriate reference values, especially when laboratory tests are obtained at nonpediatric hospitals or clinics. For example, a seemingly high GGT value in a neonate may not be abnormal; such values in this age group routinely are up to eight times higher than those observed in adults. Finally, GGT values may be elevated in response to different pharmacologic therapies, such as



anticonvulsants, so the clinician needs to know the patient's recent history of drug exposure.

#### **ALBUMIN**

A decrease in serum levels of albumin, which is synthesized in the rough endoplasmic reticulum of healthy hepatocytes, may suggest decreased hepatic production due to decreased liver function following hepatocellular disease. However, a low serum albumin concentration is a late finding in liver disease. When it is present, it suggests chronic disease. Clearly, a sudden drop in the albumin value in a patient who has longstanding disease is particularly worrisome, although such a decrease in patients who have ascites simply may reflect a change in the overall volume of distribution.

*No matter what the cause, an elevated PT value in patients who have liver disease is serious . . . . Untreated hypoprothrombinemia may lead to spontaneous bleeding and intracranial hemorrhage.*

#### **AMMONIA**

Ammonia production derives from the action of colonic bacteria on dietary proteins, and the liver plays a major role in its elimination. Clearly, a poorly functioning liver does not catabolize ammonia. Hyperammonemia and encephalopathy are classic findings of liver failure, and there is a labile correlation between the degree of encephalopathy and serum ammonia levels. However, unless the specimen is drawn in a fasting state and transported quickly to the laboratory on ice, spuriously high ammonia levels will be obtained.

#### **PROTHROMBIN TIME (PT)**

Production of coagulation factors II, VII, IX, and X depend on an adequate supply of vitamin K. Because this is a fat-soluble vitamin, vitamin K deficiency is common among individuals who have obstructive liver disease in whom bile acids do not reach the intestine. Therefore, the PT, which measures the time required for prothrombin (factor II) to be converted into thrombin, will be elevated in the presence of biliary obstruction. Malnourished indi-

viduals are also at risk for vitamin K deficiency, and many individuals who have liver disease are not in an optimal nutritional state.

PT also can be elevated in the setting of pure hepatocellular disease because vitamin K helps to catalyze the gamma-carboxylation of the aforementioned factors in the liver. A nonfunctional or a poorly functioning liver cannot carry out gamma carboxylation appropriately, despite the presence of vitamin K. This is the basis for parenteral administration (not oral) of vitamin K to patients who have elevated PT values. If this therapy corrects the PT value, liver function probably still is within normal limits, and the deficiency most likely is due to obstruction. Therefore, it is useful to remeasure the PT value after admin-

istration of vitamin K.

No matter what the cause, an elevated PT value in patients who have liver disease is serious. One of the first steps when evaluating a newborn who has cholestasis is to measure PT/PTT and administer vitamin K. Untreated hypoprothrombinemia may lead to spontaneous bleeding and intracranial hemorrhage.

#### **TRACE ELEMENT AND VITAMIN ABNORMALITIES**

Copper accumulates in the liver during cholestasis because it is excreted primarily via bile. It is possible that an interaction between copper, a pro-oxidant that generates free radicals, and a liver already injured by cholestasis (in the setting of depleted antioxidants, such as glutathione and vitamin E) contributes further to the existing liver damage.

Manganese also is excreted primarily via the biliary system and, therefore, can accumulate in the liver and cause hepatotoxicity. For this reason, we reduce or even stop manganese supplementation in total parenteral solutions used for patients who have liver disease.

Aluminum also is eliminated via biliary excretion and is hepatotoxic in large doses. Cholestasis can lead to its accumulation in the liver.

Fat-soluble vitamins (A, D, E, and K) all are absorbed because of adequate hepatic secretion of bile acids into the intestinal lumen. When bile acids are not excreted into the intestine, fat-soluble vitamins are malabsorbed. Furthermore, vitamin A and E esters require hydrolysis prior to absorption, and a bile acid-dependent intestinal esterase catalyzes this reaction. Therefore, vitamin A and E absorption is decreased further in those who have cholestasis. The liver also is responsible for one of the hydroxylation steps required to metabolize vitamin D to its active form. Clearly, impaired hepatic function will decrease vitamin D levels, and rickets is common among children who have cholestasis.

#### **Imaging and Histopathology of the Liver and Biliary Tract**

##### **ABDOMINAL ULTRASONOGRAPHY**

Abdominal ultrasonography is relatively inexpensive, easy to perform, and usually can be undertaken without sedating the patient. It allows the measurement of liver size, verification of changes in liver texture, and documentation of the presence of cystic and noncystic parenchymal lesions. Choledochal cysts and stones are detected with 95% accuracy. Ultrasonography also is useful as a screening device for space-occupying lesions of the liver and dilated bile ducts. Finally, it also allows verification of the absence of a gallbladder, which may suggest the presence of biliary atresia.

##### **CHOLESCINTIGRAPHY**

Radionuclide imaging with cholephilic radiotracers detects abnormalities in liver uptake as well as parenchymal concentrating and excretory abilities. Imaging with an N-substituted iminodiacetate (IDA) preparation labeled with technetium-99, such as diisopropyl-IDA (DISIDA) or para-isopropyl-IDA (PIPIDA), is employed in the inves-

tigation of infants who have liver disease in some institutions. These radiotracers are concentrated within the bile, thereby providing an image of bile flow, even in the presence of severe cholestasis. The appearance of the tracer within the intestinal region by 24 hours virtually excludes biliary atresia, but the converse is not true. In fact, the lack of tracer in the gut may not represent an obstructive defect, but rather a parenchymal disease process in which uptake or concentration of the tracer is poor. To facilitate bile flow, patients often receive phenobarbital (5 mg/kg per day divided in two daily doses) for 3 to 5 days prior to undergoing the scan. Phenobarbital facilitates bile flow by inducing specific liver enzymes in infants who have immature hepatic enzyme systems but no other abnormalities.

In general, radionuclide excretory scans are not essential for evaluating neonatal cholestasis. This time-consuming process potentially can delay diagnosis. Furthermore, it has high false-positive (ie, no excretion) and false-negative (ie, an apparent excretion of tracer into the intestine) yields (at least 10%) and is not very effective when serum bilirubin levels are high. Percutaneous liver biopsy never should be postponed to perform a radionuclide scan.

#### COMPUTED TOMOGRAPHY (CT) AND MAGNETIC RESONANCE IMAGING (MRI)

These two modalities rarely are necessary as first-line measures in the diagnosis of liver disease in children. However, they may be useful in specific situations. CT scanning of the liver can detect glycogen, iron, and lipid deposits within the liver parenchyma and can delineate and characterize liver masses clearly. However, CT is more expensive and technically more difficult in infants than ultrasonography, and it exposes the patient to ionizing radiation. MRI has a comparable sensitivity to CT in recognizing chemical differences in tissues and identifying tumors and infiltrates without the injection of a contrast agent or exposure of the patient to ionizing radiation. How-

ever, MRI is more expensive and cannot be used to detect calcium deposits or in patients who have implanted metal devices.

#### PERCUTANEOUS LIVER BIOPSY

Percutaneous liver biopsy is the cardinal method by which to arrive quickly at a diagnosis of underlying liver disease. It is fast, safe, and effective and usually does not require operating room time or overnight hospital admission. The histologic appearance of the liver parenchyma can be examined, and glycogen, copper, iron, and other components within the liver tissue can be quantified exactly. Pathologists can determine whether any

*. . . impaired hepatic function will decrease vitamin D levels, and rickets is common among children who have cholestasis.*

storage disorder is present or document the existence of Wilson disease (copper storage), glycogen storage disease, or neonatal iron storage disease as well as many other pathologic conditions. The histologic appearance of the tissue provides useful information about the degree of fibrosis or presence of cirrhosis and permits the diagnosis of biliary atresia, neonatal hepatitis, congenital hepatic fibrosis, and alpha 1-antitrypsin deficiency. It has been reported that percutaneous liver biopsy can provide an exact diagnosis of biliary atresia in 94% to 97% of all cases, thereby eliminating the risk of subjecting an infant who has cholestasis due to paucity of intrahepatic bile ducts to needless surgery.

#### Liver Disease of the Neonate

##### NEONATAL HEPATITIS

This relatively specific syndrome is characterized both clinically and histologically, but the pathophysiologic basis is unknown. A small percentage of cases may be associated with viral hepatitis acquired in utero or postnatally. In most cases, however, "idiopathic" neonatal hepatitis represents a very general category that includes all cases of neonatal liver dysfunction for which an etiology has not been identified. For

example, homozygous alpha 1-antitrypsin deficiency, which now is recognized easily as a specific cause of liver disease in neonates, previously was included in the idiopathic neonatal hepatitis category. Similarly, as the metabolism of bile acids is defined more clearly and specific defects are being identified, many infants previously deemed to have "neonatal hepatitis" now are being judged to have a defect in bile acid metabolism.

The hepatobiliary systems of infants and neonates are highly susceptible to injury due to age-related immaturity of metabolic processes, deficient transport proteins, or altered organellar function. These

features lead to an altered permeability or inefficient transport within the system, which facilitates the initiation or perpetuation of cholestasis. The primary focus in managing infants who have neonatal hepatitis is to conduct an exhaustive search for recognizable or treatable causes of the clinical condition. Jaundice may be present from birth or appear in the first 3 months of life. Unfortunately, the classic findings of cholestasis are not always present in the first few weeks of life of patients who have bile duct paucity, alpha 1-antitrypsin deficiency, or even biliary atresia. These infants frequently feed poorly, vomit, and appear ill, but this is not always the case.

Cholestasis is manifested by the passage of acholic stools and dark urine. The serum bilirubin level is increased, and more than 50% of the value is due to the conjugated fraction. Aminotransferase levels almost always are elevated, but to varying degrees. In general, they rarely exceed 1,000 IU/L. The AP and GGT levels are elevated only modestly, if at all. Serum albumin and PT may be abnormal, and the degree of abnormality correlates with the severity of disease at the initial presentation. Ultrasonography usually reveals the presence of a gall bladder and the absence of a cystic malformation of the biliary tree

accounting for the cholestasis. Hepatobiliary scintigraphy, if performed, reveals delayed transport of radionuclide and eventually shows a patent extrahepatic biliary tree. A severely damaged liver may have difficulty in taking up the radionuclide, which diminishes the usefulness of this test in severely ill infants. Liver biopsy usually provides the definitive diagnosis by demonstrating giant cell transformation with inflammatory infiltrates of the portal zones and an absence of bile ductule proliferation.

Management of these infants involves supportive measures and avoiding the consequences of malabsorption by ensuring adequate nutrition and delivery of fat-soluble vitamins and medium-chain triglycerides until recovery (which occurs in the majority). Liver transplantation is an alternative for those who do not respond to medical treatment.

***The major causes of liver disease observed after infancy are toxic, infectious, metabolic, autoimmune, vascular, and infiltrative.***

#### **BILIARY ATRESIA**

Biliary atresia is the result of a destructive, idiopathic inflammatory process that affects intra- and extrahepatic bile ducts. It leads to fibrosis and obliteration of the biliary tract, with the eventual development of biliary cirrhosis. It occurs worldwide, affecting an estimated 1 in 12,000 live births, and is the most frequent indication for liver transplantation among infants and children. The need for liver transplantation arises because affected patients also are subject to progressive and variably rapid development of end-stage liver disease due to a persistent intrahepatic inflammatory process.

Early differentiation of biliary atresia from idiopathic neonatal hepatitis allows for prompt surgical correction (Kasai portoenterostomy), which permits improved nutrition and maximal growth. Because cirrhosis develops rapidly, surgical correction of biliary atresia is most effective if performed before 3 months of age, which underlines the need for prompt and precise diagnosis of the cause of observed liver dysfunction in an infant.

As with idiopathic neonatal hepatitis, infants who have biliary atresia present with signs of cholestasis. Once these signs are recognized, abdominal ultrasonography can rule out the presence of a choledochal cyst. Cholescintigraphy will show good uptake of tracer and no excretion of it into the intestine, even 24 hours later. A liver biopsy confirms the diagnosis by revealing proliferation of the interlobular bile ducts, periportal fibrosis, and bile plugs in canaliculi and ductules.

Liver transplantation may become necessary if there is progressive hepatic decompensation, refractory growth failure, hepatic synthetic dysfunction, and the development of a coagulopathy or intractable portal hypertension with recurrent gastrointestinal hemorrhage or hypersplenism.

#### **OTHER CAUSES**

Other disease entities leading to liver dysfunction in the neonate and infant may be diagnosed by a combination of general tests, such as ultrasonography, and more specific tests. Structural abnormalities of the biliary tree, such as congenital hepatic fibrosis or choledochal cysts, usually are detected by ultrasonography. Liver biopsy shows the characteristic "ductal plate malformation" finding in infants who have congenital hepatic fibrosis.

Bacterial infections causing cholestasis can be identified by positive blood or urine cultures. Any history of maternal exposure to, or infection with, toxoplasmosis, syphilis, cytomegalovirus, herpes simplex, varicella zoster, and other viruses should prompt an investigation for such infections. In the case of a suspected viral infection, both serum immunoglobulin M (IgM) and IgG antibodies should be obtained. Urine often will be positive for cytomegalovirus.

Hereditary tyrosinemia, a defect of tyrosine metabolism, is suggested by disproportionate abnormalities of hepatic synthetic function, mild abnormalities in bilirubin and ami-

notransferase levels, and rickets. The presence of succinylacetone in the urine and demonstration of deficient activity of fumarylacetoacetate hydrolase (which catalyzes the final step in the oxidative catabolism of tyrosine) confirm the diagnosis. Alpha 1-antitrypsin deficiency can be screened for by protein inhibitor ZZ (PiZZ) typing and will be confirmed by the finding of characteristic periodic acid Schiff-positive alpha 1-antitrypsin granules deposited within the hepatic parenchyma on liver biopsy. Excessive storage of iron is seen on biopsy in infants who have neonatal iron storage disease. Congenital hypothyroidism, which may present with unexplained hyperbilirubinemia, is ruled out by assessment of thyroid function.

#### **Liver Disease of the Older Child**

The major causes of liver disease observed after infancy are toxic, infectious, metabolic, autoimmune, vascular, and infiltrative. Although the clinical features of causative diseases in this age group are similar to those found in adults, there are some differences. Furthermore, the relative frequency of each disorder varies with the age of the patient. Viral hepatitis occurs in patients of all ages, as does the liver disease due to cardiac or collagen vascular diseases. Disorders of fat metabolism present in late infancy and early childhood; Wilson disease usually is detected in late childhood or adolescence. Neoplastic disease of the liver in children and adolescents differs from that observed in adults.

#### **ACUTE HEPATITIS**

Although a myriad of viruses can cause hepatic inflammation, five are primarily hepatotropic: hepatitis A, B, C, D, and E. The clinical presentation of viral hepatitis varies with the pathogen. HAV infection presents most often as a flu-like illness, with malaise and signs of upper respiratory tract infection. Patients often are febrile and can be very jaundiced. The pathogen spreads primarily via the oral-fecal route. In children, the disease typically is



self-limited and often is clinically inapparent. No chronic carrier state is identified. Diagnosis of acute infection is based on the presence of anti-HAV IgM antibody in serum.

Hepatitis B virus (HBV) infection can cause both acute and chronic hepatitis and possibly the development of cirrhosis and hepatocellular carcinoma. Diagnosis rests on the demonstration of hepatitis B surface antigen (HBsAg) or anti-HBV core (anti-HB<sub>c</sub>) IgM antibody. Chronic HBV infection is associated with the persistence of HBsAg and HBV DNA.

Hepatitis C virus (HCV) causes acute hepatitis, which progresses to chronic disease in more than 70% of affected individuals. Although end-stage liver disease can occur in up to 10% of patients, fulminant hepatitis rarely has been described. Diagnosis is based on the detection of anti-HCV antibodies and confirmed by polymerase chain reaction for HCV RNA.

Hepatitis D virus (HDV) infection occurs only in patients who have HBV infection. HDV usually aggravates liver disease in a patient who has hepatitis B and always should be considered in those who have particularly aggressive HBV disease. HDV is common in the Mediterranean basin and less common in North America, where it is associated primarily with intravenous drug abuse.

Hepatitis E virus (HEV) occurs in epidemics in parts of the world that have poor sanitary conditions. Cases diagnosed in North America have involved patients who imported the virus from abroad. It can be a particularly devastating disease in pregnant women.

### CHRONIC HEPATITIS

This traditionally is defined as an inflammatory condition of the liver in which the biochemical and histologic abnormalities persist for more than 6 months. However, irreversible changes may occur in children within those 6 months. Most acute hepatitis resolves within 3 months in children, after which the etiology of the observed liver disease must be pursued aggressively because many of the diseases causing chronic hep-

atitis in children respond to specific medical therapy. Chronic hepatitis in children is the result of a viral infection; an autoimmune process; exposure to hepatotoxic drugs; or cardiac, metabolic, or systemic disorders.

### *Copper accumulates in the liver during cholestasis . . . an interaction between copper . . . and a liver already injured by cholestasis . . . contributes further to the existing liver damage.*

#### AUTOIMMUNE HEPATITIS (AIH)

AIH is a hepatic inflammation associated with the presence of circulating autoantibodies in the absence of other recognized causes of liver disease. At least two types are described: Type I AIH is more common among females and is characterized by a positive antinuclear antibody, and Type II AIH involves anti-liver-kidney microsomal antibodies. Other autoimmune diseases may coexist, including thyroiditis, diabetes, hemolytic anemia, and erythema nodosum. Laboratory evaluation reveals elevation of aminotransferases (often very high) and a variable degree of hyperbilirubinemia, the greater part of which is conjugated. Serum gamma globulin concentrations are elevated in nearly all patients. AP and GGT values usually are normal or only mildly elevated. Liver biopsy reveals inflammatory infiltrates of the limiting plate and intralobular zones, with piecemeal necrosis, distortion of lobular architecture, and even bridging fibrosis in severe cases.

#### OTHER LIVER DISEASES

Sclerosing cholangitis is characterized by a chronic inflammatory process of the intra- or extrahepatic biliary tree. It may be primary (without evidence of another underlying disease and of unknown etiology) and usually is associated with inflammatory bowel disease. Secondary sclerosing cholangitis results from stones, postoperative strictures, or tumors. Children may present with jaundice, pruritus, and fatigue. Elevated AP levels are very characteristic, but there is no specific marker of the disease. Biopsies show a typical concentric fibrosis

around the interlobular bile ducts ("onion skin" appearance). Cholangiography or endoscopic retrograde cholangiopancreatography is necessary to establish the diagnosis. Treatment involves administration of fat-soluble vitamins and ursodeoxy-

cholic acid, a naturally occurring choleric bile acid that appears to improve pruritus in affected patients. Unfortunately, the liver disease progresses in most patients, and cirrhosis develops. Liver transplantation ultimately is necessary for long-term survival.

Wilson disease is an autosomal recessive disorder caused by a defect in biliary copper excretion, in which excessive copper accumulation leads to cirrhosis. The excess copper is deposited in the cornea, kidneys, and brain, resulting in extrahepatic manifestations of the disease. Although the clinicopathologic presentation may be extremely variable, Wilson disease needs to be included in the differential diagnosis of any child who presents with liver disease, neurologic abnormalities, behavioral changes, or Kayser-Fleischer rings. Serum ceruloplasmin, a carrier of copper, usually, but not invariably, is decreased. Definitive diagnosis requires evaluation of 24-hour urinary copper excretion and copper quantification in liver tissue obtained by biopsy. Wilson disease may present as fulminant hepatic failure, usually in association with a hemolytic crisis due to the toxic effect of copper on red blood cells. Therapy is chelation of copper with penicillamine, which allows for its excretion into the urine. Because the prognosis depends on early treatment and individual responsiveness to chelation therapy, it is important to consider this diagnosis in every child who has signs of chronic liver disease.

Ischemic hepatitis results from congestive heart failure, shock (eg, dehydration), asphyxia, cardiorespiratory arrest, or seizures. Typically, aminotransferases are elevated



**TABLE 9. Nontransplant Options for Children Who Have Liver Disease**

• Replacement of the deficient abnormal end product, such as oral administration of primary bile acids (in patients who have abnormalities of bile acid biosynthesis)
• Depletion of the stored substance (eg, antioxidant cocktails and chelation in neonatal iron storage disease)
• Use of metabolic inhibitors (eg, NTBC in tyrosinemia)
• Induction of enzymes (eg, phenobarbital therapy in Crigler-Najjar syndrome type II)
• Dietary restriction of the substrate (eg, galactose in galactosemia)
• Molecular manipulations (eg, inhibition of polymerization of alpha 1-antitrypsin)
• Receptor-based, targeted enzyme replacement therapy
• Gene therapy
• Hepatocyte transplantation (eg, fulminant liver failure)

in the absence of other markers of severe liver disease. The disorder is due to hypotension/hypoperfusion to the liver during one of the aforementioned events that leads to the liver being damaged as an “innocent bystander” of the original process. Ischemic hepatitis may resemble infectious hepatitis, but it is distinguished easily by rapidly decreasing aminotransferase levels in the days following the initial insult without increasing coagulopathy or hyperbilirubinemia.

Infiltrative disorders of the liver are observed with leukemia, lymphoma, and neuroblastoma, but these entities usually are discovered quickly upon presentation. Likewise, primary liver tumors are identified readily in the child who presents with hepatomegaly or abdominal distention or mass. Less commonly, children present initially with jaundice and failure to thrive. Hepato-

blastoma, hepatocarcinoma, and hemangioendothelioma account for almost two thirds of all childhood hepatic tumors. Hepatocellular carcinoma tends to occur later in life than hepatoblastoma and is more common among children who have a history of chronic liver disease (eg, chronic hepatitis B). Serum alpha-fetoprotein levels usually are elevated. CT scan typically reveals low-density lesions and indicates whether the mass is solitary or multifocal. Surgical excision of a solitary tumor or radiation/chemotherapy is the treatment of choice.

### Conclusion

Identifying the presence of serious liver disease in a pediatric patient at the initial presentation is of cardinal importance. Early recognition of babies who have biliary atresia is critical for optimal medical or surgical intervention.

An exciting recent development is the availability of multiple non-transplant options for the treatment of liver disease (Table 9). These novel management strategies are more cost-effective, but also reduce the use of valuable donor livers, making these organs available for patients who do not have other treatment options. In the future, definitive therapy, such as targeted enzyme replacement or gene therapy, may be available for certain metabolic disorders. In view of these exciting prospects, it becomes of great importance to assess the presence of liver disease correctly and quickly in children to allow them to grow and be as healthy as possible until they can reach an age at which definitive therapy may be available.

### SUGGESTED READING

- Balistreri WF. Acute and chronic viral hepatitis. In: Suchy F, ed: *Liver Disease in Children*. St. Louis, Mo: Mosby-Year Book; 1994:460–509
- Balistreri WF. Neonatal cholestasis - medical progress. *J Pediatr*. 1985;106:171–184
- Balistreri WF. Nontransplant option for the treatment of metabolic liver disease: saving livers while saving lives. *Hepatology*. 1994;19:782–787
- D’Agata ID, Jonas MM, Perez-Atayde A, Guay-Woodforde L. Cystic disease of liver and kidney. *Semin Liver Dis*. 1994;14:215–228
- Kleinman RE, D’Agata ID, Vacanti, JP. Liver transplantation. In: Walker WA, Durie PR, Hamilton JR, Walker-Smith JA, Watkins JB, eds. *Pediatric Gastrointestinal Disease*. St Louis, Mo: Mosby-Year Book;1996:1340–1361
- Mews C, Sinatra F. Chronic liver disease in children. *Pediatr Rev*. 1993;14:436–443
- Mieli Vergani G, Portman B, Howard ER, et al. Late referral for biliary atresia - missed opportunities for effective surgery. *Lancet*. 1989;1:421–423

**PIR QUIZ**

Quiz also available online at [www.pedsinreview.org](http://www.pedsinreview.org).

1. A 15-year-old girl who is being evaluated for poor school performance and acting-out behaviors is noted to have a large, firm liver. Kayser-Fleischer rings are apparent on ophthalmologic examination. Determination of which of the following is *most* likely to confirm the diagnosis in this patient?
  - A. Hepatic copper concentration.
  - B. Hepatic iron concentration.
  - C. Hepatitis B antibody titers.
  - D. Serum alpha 1-antitrypsin level.
  - E. Serum chloride level.
2. A 3-year-old girl who has cholestasis and is malnourished is suspected of having a nutrient deficiency. Which one of the following clinical findings is *most* likely to be present in this child?
  - A. Megaloblastic anemia.
  - B. Neuritis.
  - C. Pellagra.
  - D. Photophobia.
  - E. Rachitic rosary.

3. A 3-week-old infant who has jaundice and pale stools has a total bilirubin of 166.6 mcmol/L (9.8 mg/dL) and a conjugated fraction of 102 mcmol/L (6.0 mg/dL). Which of the following clinical features is *most* suggestive of a diagnosis of biliary atresia?
  - A. Cholestasis associated with a dietary change.
  - B. Failure to thrive.
  - C. Familial occurrence.
  - D. Male gender.
  - E. Polysplenia syndrome.
4. Which of the following nutrients should be reduced in the total parental nutrition given to patients who have chronic cholestasis?
  - A. Carbohydrates.
  - B. Copper.
  - C. Fat-soluble vitamins.
  - D. Medium-chain triglycerides.
  - E. Water-soluble vitamins.

5. A 4-week-old infant is jaundiced. Findings include weight and length at the 75th percentile for age; icterus; a firm liver with a span of 5 cm and palpable 3 cm below the right costal margin; splenomegaly; total bilirubin, 107.1 mcmol/L (6.3 mg/dL); direct bilirubin, 71.4 mcmol/L (4.2 mg/dL); alanine aminotransferase activity, 130 U/L; aspartate aminotransferase activity, 143 U/L; and gamma-glutamyl transferase activity, 950 U/L. Of the following, the *best* study to evaluate the excretion of bile from this infant's liver is:
  - A. Computed tomography of the liver.
  - B. Cholescintigraphy.
  - C. Hepatic ultrasonography.
  - D. Measurement of fumarylacetoacetate hydrolase activity.
  - E. Measurement of the serum alpha 1-antitrypsin level.

United States Postal Service

**Statement of Ownership, Management, and Circulation**

1. Publication Title <b>Pediatrics in Review</b>		2. Publication Number 0 1 9 1 - 9 6 0 1		3. Filing Date September 8, 1999	
4. Issue Frequency Monthly		5. Number of Issues Published Annually 12		6. Annual Subscription Price \$140	
7. Complete Mailing Address of Known Office of Publication (Not printer) (Street, city, county, state, and ZIP+4) American Academy of Pediatrics 141 Northwest Point Blvd. Elk Grove Village, IL 60007-1098				Contact Person Angela Brooks Green Telephone 847-981-7895	
8. Complete Mailing Address of Headquarters or General Business Office of Publisher (Not printer) American Academy of Pediatrics 141 Northwest Point Blvd. Elk Grove Village, IL 60007-1098					
9. Full Names and Complete Mailing Addresses of Publisher, Editor, and Managing Editor (Do not leave blank)					
Publisher (Name and complete mailing address) American Academy of Pediatrics 141 Northwest Point Blvd.		Cook County Elk Grove Village, IL 60007-1098			
Editor (Name and complete mailing address) Robert J. Haggerty School of Medicine and Dentistry 601 Elmwood Ave. Rochester, NY 14642					
Managing Editor (Name and complete mailing address) Angela Brooks Green American Academy of Pediatrics 141 Northwest Point Blvd. Elk Grove Village, IL 60007-1098					
10. Owner (Do not leave blank. If the publication is owned by a corporation, give the name and address of the corporation immediately followed by the names and addresses of all stockholders owning or holding 1 percent or more of the total amount of stock. If not owned by a corporation, give the names and addresses of the individual owners. If owned by a partnership or other unincorporated firm, give its name and address as well as those of each individual owner. If the publication is published by a nonprofit organization, give its name and address.)					
Full Name		Complete Mailing Address			
American Academy of Pediatrics		141 Northwest Point Blvd.			
(non-profit organization under section 501 (c) (3) of the Internal Revenue code)		Elk Grove Village, IL 60007-1098			
11. Known Bondholders, Mortgagees, and Other Security Holders Owning or Holding 1 Percent or More of Total Amount of Bonds, Mortgages, or Other Securities. If none, check box <input checked="" type="checkbox"/> None					
Full Name		Complete Mailing Address			
12. Tax Status (For completion by nonprofit organizations authorized to mail at nonprofit rates) (Check one) The purpose, function, and nonprofit status of this organization and the exempt status for federal income tax purposes: <input checked="" type="checkbox"/> Has Not Changed During Preceding 12 Months <input type="checkbox"/> Has Changed During Preceding 12 Months (Publisher must submit explanation of change with this statement)					

PS Form 3526, September 1998

(See Instructions on Reverse)

13. Publication Title <b>Pediatrics in Review</b>		14. Issue Date for Circulation Data Below September 1999	
15. Extent and Nature of Circulation		Average No. Copies Each Issue During Preceding 12 Months	No. Copies of Single Issue Published Nearest to Filing Date
a. Total Number of Copies (Net press run)		37,155	37,555
b. Paid and/or Requested Circulation	(1) Paid/Requested Outside-County Mail Subscriptions Stated on Form 3541 (include advertiser's proof and exchange copies)	30,589	32,623
	(2) Paid In-County Subscriptions (include advertiser's proof and exchange copies)		
	(3) Sales Through Dealers and Carriers, Street Vendors, Counter Sales, and Other Non-USPS Paid Distribution		
	(4) Other Classes Mailed Through the USPS		
c. Total Paid and/or Requested Circulation (Sum of 15b (1), (2), (3), and (4))		30,589	32,623
d. Free Distribution by Mail (Same as 15c, complement any, and other free)	(1) Outside-County as Stated on Form 3541	0	0
	(2) In-County as Stated on Form 3541		
	(3) Other Classes Mailed Through the USPS		
e. Free Distribution Outside the Mail (Carriers or other means)		7	7
f. Total Free Distribution (Sum of 15d and 15e)		7	7
g. Total Distribution (Sum of 15c and 15f)		30,596	32,630
h. Copies not Distributed		6,559	4,925
i. Total (Sum of 15g and h.)		37,155	37,555
j. Percent Paid and/or Requested Circulation (15c, divided by 15g, times 100)		100%	100%

16. Publication of Statement of Ownership  
 Publication required. Will be printed in the **November 1999** issue of this publication.  Publication not required.

17. Signature and Title of Editor, Publisher, Business Manager, or Owner  
*Angela Brooks Green* Date **9/8/99**

I certify that all information furnished on this form is true and complete. I understand that anyone who furnishes false or misleading information on this form or who omits material or information requested on the form may be subject to criminal sanctions (including fines and imprisonment) and/or civil sanctions (including civil penalties).

**Instructions to Publishers**

1. Complete and file one copy of this form with your postmaster annually on or before October 1. Keep a copy of the completed form for your records.
2. In cases where the stockholder or security holder is a trustee, include in items 10 and 11 the name of the person or corporation for whom the trustee is acting. Also include the names and addresses of individuals who are stockholders who own or hold 1 percent or more of the total amount of bonds, mortgages, or other securities of the publishing corporation. In item 11, if none, check the box. Use blank sheets if more space is required.
3. Be sure to furnish all circulation information called for in item 15. Free circulation must be shown in items 15d, e, and f.
4. Item 15h, Copies not Distributed, must include (1) newsstand copies originally stated on Form 3541, and returned to the publisher, (2) estimated returns from news agents, and (3) copies for office use, leftovers, spoiled, and all other copies not distributed.
5. If the publication had Periodicals authorization as a general or requester publication, this Statement of Ownership, Management, and Circulation must be published; it must be printed in any issue in October or, if the publication is not published during October, the first issue printed after October.
6. In item 16, indicate the date of the issue in which this Statement of Ownership will be published.
7. Item 17 must be signed.

**Failure to file or publish a statement of ownership may lead to suspension of Periodicals authorization.**

PS Form 3526, September 1998 (Reverse)